Settings

1
2
3
4
5
6
7
8
9

Item 1 of 9
Question Id: 1958

Mark | Previous | Next | Full Screen | Tutorial | Lab Values | Notes | Calculator | Reverse Color | Text Zoom | Settings

A 32-year-old woman comes to the office due to a small amount of malodorous vaginal discharge. She is sexually active with her male partner and uses condoms sporadically. The patient also requests testing for all sexually transmitted diseases as she is unsure if her partner is monogamous. She smokes 2 packs of cigarettes daily and had an abnormal Papanicolaou test in the past. Speculum examination reveals thin gray discharge. Wet mount of the discharge shows large, atypical vaginal epithelial cells and no protozoa. Application of potassium hydroxide (KOH) solution to the discharge yields a strong fishy odor. Which of the following is the best treatment option for this patient?

A. Acyclovir
B. Azithromycin
C. Clindamycin
D. Fluconazole
E. Penicillin

Submit

Block Time Remaining: 00:00:02
TUTOR

2 | Feedback | Suspend | End Block

A 32-year-old woman comes to the office due to a small amount of malodorous vaginal discharge. She is sexually active with her male partner and uses condoms sporadically. The patient also requests testing for all sexually transmitted diseases as she is unsure if her partner is monogamous. She smokes 2 packs of cigarettes daily and had an abnormal Papanicolaou test in the past. Speculum examination reveals thin gray discharge. Wet mount of the discharge shows large, atypical vaginal epithelial cells and no protozoa. Application of potassium hydroxide (KOH) solution to the discharge yields a strong fishy odor. Which of the following is the best treatment option for this patient?

A. Acyclovir (1%)
B. Azithromycin (25%)
✓ C. Clindamycin (54%)
D. Fluconazole (13%)
E. Penicillin (4%)

Omitted
Correct answer
C

54%
Answered correctly

03 secs
Time Spent

05/17/2020
Last Updated

Explanation

Differential diagnosis of vaginitis			
Diagnosis	**Bacterial vaginosis** (*Gardnerella vaginalis*)	**Trichomoniasis** (*Trichomonas vaginalis*)	**Candida vaginitis** (*Candida albicans*)

Differential diagnosis of vaginitis

Diagnosis	Bacterial vaginosis (*Gardnerella vaginalis*)	Trichomoniasis (*Trichomonas vaginalis*)	Candida vaginitis (*Candida albicans*)
Examination	• Thin, off-white discharge with fishy odor • No inflammation	• Thin, yellow-green, malodorous, frothy discharge • Vaginal inflammation	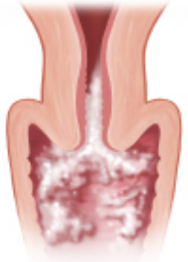 • Thick, "cottage cheese" discharge • Vaginal inflammation
Laboratory findings	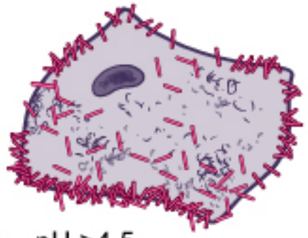 • pH >4.5 • Clue cells • Positive whiff test (amine odor with KOH)	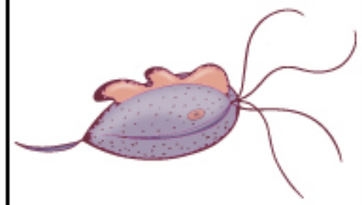 • pH >4.5 • Motile trichomonads	• Normal pH (3.8-4.5) • Pseudohyphae
Treatment	Metronidazole or clindamycin	Metronidazole; treat sexual partner	Fluconazole

KOH = potassium hydroxide

©UWorld

This patient has **bacterial vaginosis (BV)**, which is caused by alterations in the normal vaginal flora, including loss of lactobacilli and overgrowth of mixed anaerobes. The concentration of the facultative, anaerobic gram-variable rod, *Gardnerella vaginalis*, is most significantly increased. Patients commonly have **gray or clear discharge** with a **"fishy" odor**. Although BV is not a sexually transmitted disease, it is associated with sexual activity. Addition of **potassium hydroxide (KOH)** to a sample of the discharge (**"whiff" test**) makes the odor especially prominent. This odor is caused by volatilization of **amines** produced by *G vaginalis* and other anaerobes. The presence of **clue cells** on wet mount microscopy of the discharge is also characteristic.

Clindamycin and **metronidazole** are effective treatment options for BV. Clindamycin is a bacteriostatic drug that inhibits protein translation by binding to the 50s ribosomal subunit. Metronidazole is bactericidal and damages the DNA of facultative anaerobes.

(Choice A) Acyclovir is a guanosine chain analog that inhibits multiplication of herpes simplex virus, a double-stranded DNA virus. Genital herpes typically presents with painful vaginal or vulvar vesicles.

(Choice B) *Chlamydia trachomatis* is a gram-negative bacterium that can infect the columnar epithelium of the cervix (eg, cervicitis) and urethra in addition to the lungs and eyes. Diagnosis is via polymerase chain reaction, and treatment is with azithromycin, a bacteriostatic macrolide antibiotic.

(Choice D) *Candida albicans* is the most common cause of fungal vaginitis. Patients present with intense vaginal pruritus, labial erythema, and a white, curd-like discharge. KOH examination shows yeast forms and pseudohyphae. Treatment is with azole antifungals (eg, fluconazole), which function by inhibiting 14α-demethylase, a cytochrome P450 enzyme.

(Choice E) Syphilis presents with a painless chancre, followed by a rash and systemic symptoms; it is caused by the gram-negative spirochete *Treponema pallidum*. Vaginal discharge is not typically seen. It is treated with penicillin, a bactericidal β-lactam antibiotic that works by inhibiting cell wall synthesis.

Educational objective:
Bacterial vaginosis is a vaginal infection diagnosed by the presence of clue cells and a positive amine "whiff" test with potassium hydroxide (KOH). The pathogenesis involves a loss of lactobacilli in the normal vaginal flora and overgrowth of *Gardnerella vaginalis*. It is treated with clindamycin or metronidazole.

Clindamycin and **metronidazole** are effective treatment options for BV. Clindamycin is a bacteriostatic drug that inhibits protein translation by binding to the 50s ribosomal subunit. Metronidazole is bactericidal and damages the DNA of facultative anaerobes.

(Choice A) Acyclovir is a guanosine chain analog that inhibits multiplication of herpes simplex virus, a double-stranded DNA virus. Genital herpes typically presents with painful vaginal or vulvar vesicles.

(Choice B) *Chlamydia trachomatis* is a gram-negative bacterium that can infect the columnar epithelium of the cervix (eg, cervicitis) and urethra in addition to the lungs and eyes. Diagnosis is via polymerase chain reaction, and treatment is with azithromycin, a bacteriostatic macrolide antibiotic.

(Choice D) *Candida albicans* is the most common cause of fungal vaginitis. Patients present with intense vaginal pruritus, labial erythema, and a white, curd-like discharge. KOH examination shows yeast forms and pseudohyphae. Treatment is with azole antifungals (eg, fluconazole), which function by inhibiting 14α-demethylase, a cytochrome P450 enzyme.

(Choice E) Syphilis presents with a painless chancre, followed by a rash and systemic symptoms; it is caused by the gram-negative spirochete *Treponema pallidum*. Vaginal discharge is not typically seen. It is treated with penicillin, a bactericidal β-lactam antibiotic that works by inhibiting cell wall synthesis.

Educational objective:
Bacterial vaginosis is a vaginal infection diagnosed by the presence of clue cells and a positive amine "whiff" test with potassium hydroxide (KOH). The pathogenesis involves a loss of lactobacilli in the normal vaginal flora and overgrowth of *Gardnerella vaginalis*. It is treated with clindamycin or metronidazole.

References

- ACOG Practice Bulletin. Clinical management guidelines for obstetrician-gynecologists, Number 72, May 2006:Vaginitis.

Pathology	Infectious Diseases	Bacterial vaginosis
Subject	System	Topic

Copyright © UWorld. All rights reserved.

Settings

1
2
3
4
5
6
7
8
9

Item 2 of 9
Question Id: 15438

Mark | Previous | Next | Full Screen | Tutorial | Lab Values | Notes | Calculator | Reverse Color | Text Zoom | Settings

A 54-year-old Sudanese immigrant is evaluated for several months of intermittent dysuria and gross hematuria. The patient notes that he passes blood at the end of urination but has no associated pain. Cystoscopy reveals erythematous areas in the bladder mucosa. Multiple biopsies are taken from the affected sites; histopathological findings are shown in the image below.

Block Time Remaining: 00:00:03
TUTOR

2 | Feedback | Suspend | End Block

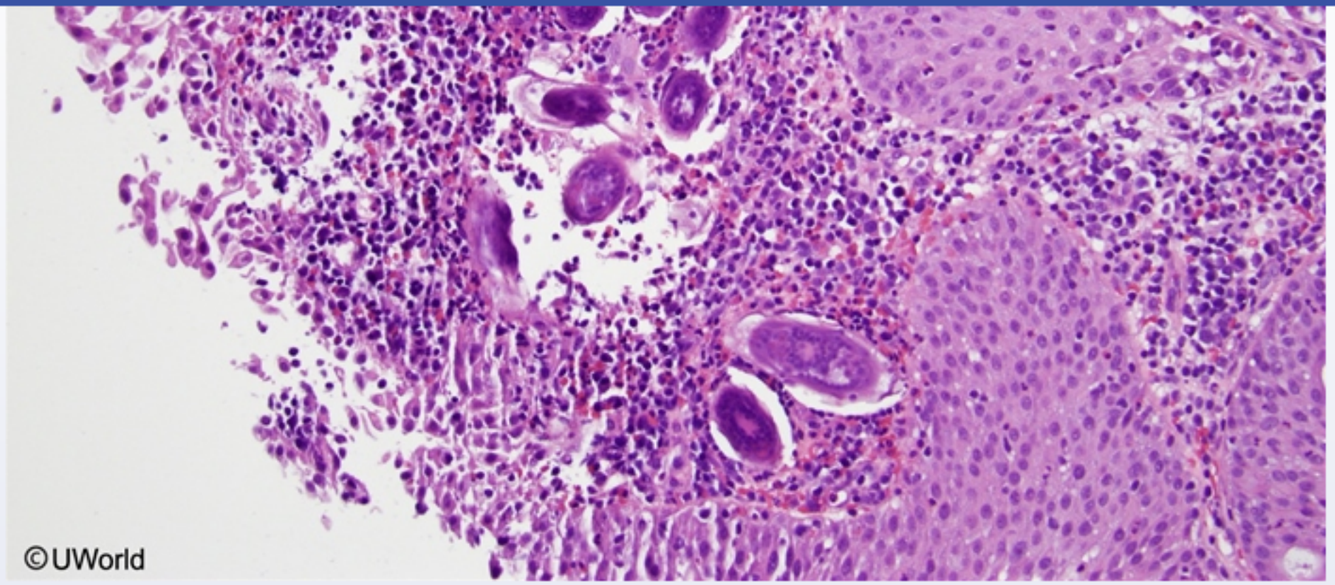

Which of the following most likely predisposed this patient to his current condition?

- A. Chronic urinary tract obstruction
- B. Contaminated water exposure
- C. Cytotoxic immunosuppressant use
- D. Extensive cigarette smoking
- E. Urea-splitting bacterial infection

Submit

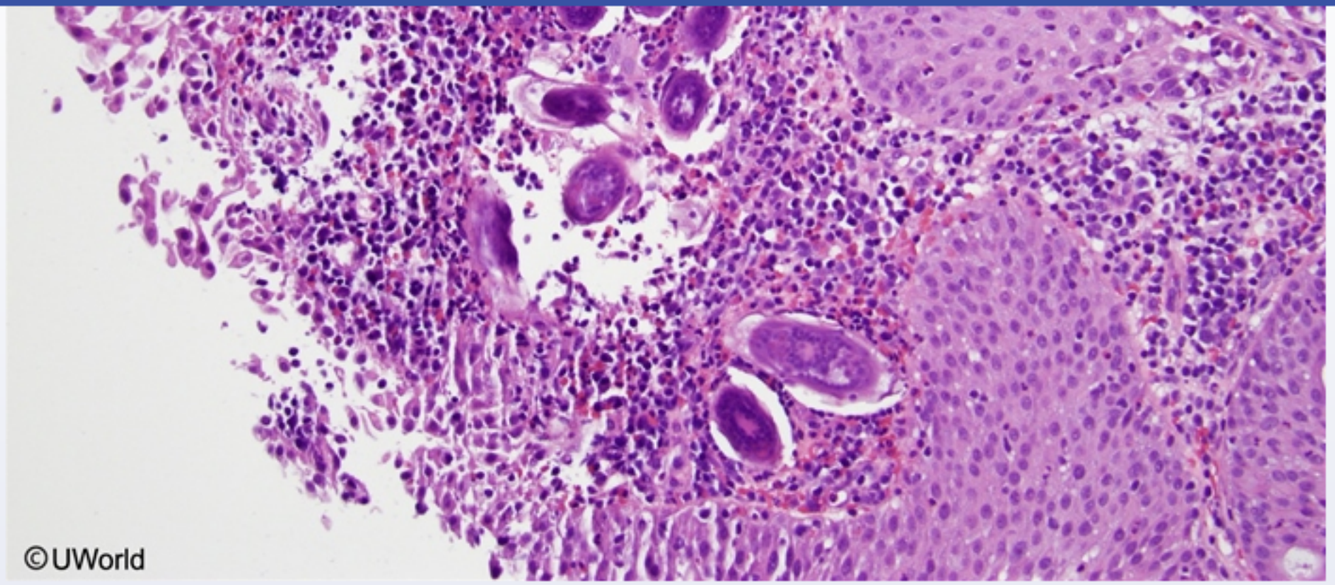

Which of the following most likely predisposed this patient to his current condition?

- A. Chronic urinary tract obstruction (2%)
- ✓ B. Contaminated water exposure (77%)
- C. Cytotoxic immunosuppressant use (1%)
- D. Extensive cigarette smoking (15%)
- E. Urea-splitting bacterial infection (2%)

Omitted
Correct answer

77%
Answered correctly

04 secs
Time Spent

04/09/2020
Last Updated

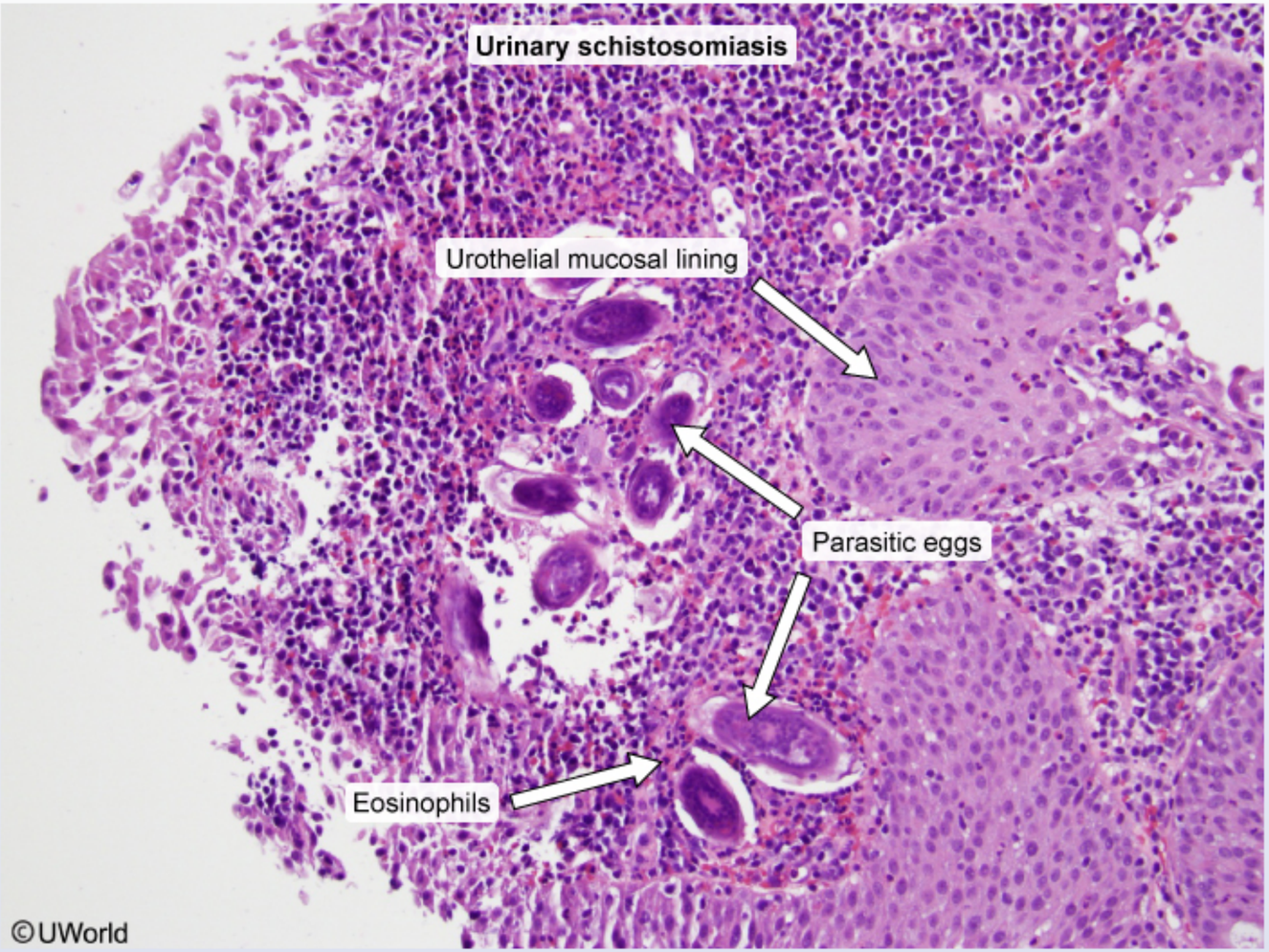

Schistosomiasis is a parasitic blood fluke infection endemic to rural areas of sub-Saharan Africa, Asia, and South America. Transmission occurs when humans **bathe in freshwater** ponds, lakes, or rivers contaminated with cercariae from **infected snails**. Cercariae penetrate the dermis and travel to the liver, where they evolve into adult worms and subsequently migrate into the venules in the walls of the intestines, colon, or bladder.

Schistosomiasis is a parasitic blood fluke infection endemic to rural areas of sub-Saharan Africa, Asia, and South America. Transmission occurs when humans **bathe in freshwater** ponds, lakes, or rivers contaminated with cercariae from **infected snails**. Cercariae penetrate the dermis and travel to the liver, where they evolve into adult worms and subsequently migrate into the venules in the walls of the intestines, colon, or bladder.

Because adult schistosomes absorb host proteins and display host antigens on their surface, they are relatively protected from immune recognition and generally do not cause symptoms. However, adult worms shed **eggs** into the circulation that travel through host tissues and induce **eosinophilic granulomatous inflammation** and fibrosis (as seen in the image above). This can lead to indolent symptoms in the liver, spleen, bowel wall, and genitourinary system. One characteristic manifestation of genitourinary schistosomiasis is the development of hematuria at the end of voiding **("terminal hematuria")** due to bladder wall inflammation and ulcers; urinary calcifications, obstruction, and bladder cancer may eventually develop.

(Choice A) Benign prostatic hyperplasia can cause chronic urinary tract obstruction. Patients usually have difficulty voiding urine (eg, slow stream, hesitancy), frequency, urgency, and/or nocturia.

(Choice C) Cyclophosphamide is a common cause of hemorrhagic cystitis in patients undergoing chemotherapy for cancer or chronic rheumatologic conditions. Cystoscopy may show bladder irritation, but eggs would not be seen on biopsy.

(Choice D) Cigarette smoking is a major risk factor for the development of bladder cancer (usually transitional cell carcinoma), which classically presents with painless hematuria. However, cystoscopy generally shows a mass, and biopsy would reveal malignant cells, not eggs.

(Choice E) Genitourinary infections with bacteria that split urea such as *Proteus mirabilis* are frequently associated with the formation of urinary stones. Nephrolithiasis can cause hematuria but is usually very painful.

Educational objective:
Schistosomiasis is a parasitic blood fluke infection that is associated with bathing in freshwater contaminated with cercariae from infected snails. Patients often are asymptomatic for months or years but may eventually develop eosinophilic granulomatous inflammation in the liver, spleen, gastrointestinal tract, or genitourinary system. One common manifestation of genitourinary schistosomiasis is painless terminal hematuria; eggs can often be identified in the urine or on biopsy.

Because adult schistosomes absorb host proteins and display host antigens on their surface, they are relatively protected from immune recognition and generally do not cause symptoms. However, adult worms shed **eggs** into the circulation that travel through host tissues and induce **eosinophilic granulomatous inflammation** and fibrosis (as seen in the image above). This can lead to indolent symptoms in the liver, spleen, bowel wall, and genitourinary system. One characteristic manifestation of genitourinary schistosomiasis is the development of hematuria at the end of voiding **("terminal hematuria")** due to bladder wall inflammation and ulcers; urinary calcifications, obstruction, and bladder cancer may eventually develop.

(Choice A) Benign prostatic hyperplasia can cause chronic urinary tract obstruction. Patients usually have difficulty voiding urine (eg, slow stream, hesitancy), frequency, urgency, and/or nocturia.

(Choice C) Cyclophosphamide is a common cause of hemorrhagic cystitis in patients undergoing chemotherapy for cancer or chronic rheumatologic conditions. Cystoscopy may show bladder irritation, but eggs would not be seen on biopsy.

(Choice D) Cigarette smoking is a major risk factor for the development of bladder cancer (usually transitional cell carcinoma), which classically presents with painless hematuria. However, cystoscopy generally shows a mass, and biopsy would reveal malignant cells, not eggs.

(Choice E) Genitourinary infections with bacteria that split urea such as *Proteus mirabilis* are frequently associated with the formation of urinary stones. Nephrolithiasis can cause hematuria but is usually very painful.

Educational objective:
Schistosomiasis is a parasitic blood fluke infection that is associated with bathing in freshwater contaminated with cercariae from infected snails. Patients often are asymptomatic for months or years but may eventually develop eosinophilic granulomatous inflammation in the liver, spleen, gastrointestinal tract, or genitourinary system. One common manifestation of genitourinary schistosomiasis is painless terminal hematuria; eggs can often be identified in the urine or on biopsy.

Pathology	Infectious Diseases	Schistosomiasis
Subject	System	Topic

Copyright © UWorld. All rights reserved.

A 73-year-old woman comes to the emergency department with a 3-day history of worsening breathlessness and cough productive of thick, rust-colored sputum. The patient has a longstanding history of hypertension. Temperature is 38.3 C (101 F), blood pressure is 130/68 mm Hg, pulse is 102/min, and respirations are 24/min. BMI is 27 kg/m^2. Jugular venous pressure is normal and there is no lower extremity edema. Heart sounds are normal with no murmur. Lung auscultation reveals left lower lobe crackles and bronchial breath sounds. Leukocyte count is 14,000/mm^3 with 80% neutrophils and 7% bands, hemoglobin is 13.6 g/dL, and platelets are 400,000/mm^3. Serum levels of which of the following are most likely to be elevated in this patient?

A. B-type natriuretic peptide

B. Cold agglutinins

C. Prealbumin

D. Procalcitonin

E. Transferrin

Submit

A 73-year-old woman comes to the emergency department with a 3-day history of worsening breathlessness and cough productive of thick, rust-colored sputum. The patient has a longstanding history of hypertension. Temperature is 38.3 C (101 F), blood pressure is 130/68 mm Hg, pulse is 102/min, and respirations are 24/min. BMI is 27 kg/m^2. Jugular venous pressure is normal and there is no lower extremity edema. Heart sounds are normal with no murmur. Lung auscultation reveals left lower lobe crackles and bronchial breath sounds. Leukocyte count is 14,000/mm^3 with 80% neutrophils and 7% bands, hemoglobin is 13.6 g/dL, and platelets are 400,000/mm^3. Serum levels of which of the following are most likely to be elevated in this patient?

A. B-type natriuretic peptide (11%)
B. Cold agglutinins (24%)
C. Prealbumin (10%)
✓ D. Procalcitonin (24%)
E. Transferrin (29%)

Omitted
Correct answer
D

24%
Answered correctly

01 sec
Time Spent

01/24/2020
Last Updated

Explanation

Acute phase reactants (APRs) are proteins whose serum concentrations change by ≥25% during periods of inflammation. Several APRs have diagnostic and prognostic utility and can be interpreted on the basis of serum concentrations:

- **Positive APRs** (serum levels rise in acute inflammatory states) include fibrinogen, C-reactive protein, ferritin, hepcidin, ceruloplasmin,

Acute phase reactants (APRs) are proteins whose serum concentrations change by ≥25% during periods of inflammation. Several APRs have diagnostic and prognostic utility and can be interpreted on the basis of serum concentrations:

- **Positive APRs** (serum levels rise in acute inflammatory states) include fibrinogen, C-reactive protein, ferritin, hepcidin, ceruloplasmin, haptoglobin, von Willebrand factor, and complement. The erythrocyte sedimentation rate (the time required for erythrocytes to settle from suspension) is an indirect measure of positive APRs.
- **Negative APRs** (serum levels fall in acute inflammatory states) include albumin, transferrin, and transthyretin (prealbumin).

Procalcitonin, a precursor of calcitonin produced by monocytes and the C cells of the thyroid, is a unique APR that has positive and negative properties. Levels **rise** in response to **bacterial toxins** and **fall** in response to **viral infections**, and therefore levels can suggest the etiology of community-acquired pneumonia. This patient has lobar pneumonia manifesting with fever, rust-colored sputum, and neutrophil-predominant leukocytosis, likely due to a bacterial infection (eg, *Streptococcus pneumoniae*). Therefore, procalcitonin levels are expected to be elevated.

(Choice A) B-type natriuretic peptide is secreted by the ventricles in response to elevated ventricular filling pressure, which is seen in decompensated heart failure. Patients with heart failure often have elevated jugular venous pressure and lower extremity edema, pulmonary examination findings are usually bilateral, and fevers and leukocytosis would not be expected.

(Choice B) Cold agglutinins (ie, IgM against erythrocyte I antigen) are nonspecific but often seen in patients with *Mycoplasma pneumoniae*. However, patients with *M pneumoniae* typically present with a dry cough and pharyngitis, and laboratory results demonstrate a mild hemolytic anemia with a normal leukocyte count. When pneumonia occurs due to *M pneumoniae*, examination findings are characteristically scattered and bilateral.

(Choices C and E) Prealbumin (transthyretin) and transferrin are negative APRs and would be decreased in this acutely ill patient. Prealbumin levels are also decreased in cases of malnutrition and may be helpful in evaluation of nutritional status. Transferrin is also used to determine iron status.

Educational objective:
Acute phase reactants (APRs) are proteins whose serum concentrations change by ≥25% during periods of inflammation. Procalcitonin is a unique APR that can rise or fall depending on the etiology of the infection; elevated levels correlate with a bacterial source, whereas low levels

properties. Levels **rise** in response to **bacterial toxins** and **fall** in response to **viral infections**, and therefore levels can suggest the etiology of community-acquired pneumonia. This patient has lobar pneumonia manifesting with fever, rust-colored sputum, and neutrophil-predominant leukocytosis, likely due to a bacterial infection (eg, *Streptococcus pneumoniae*). Therefore, procalcitonin levels are expected to be elevated.

(Choice A) B-type natriuretic peptide is secreted by the ventricles in response to elevated ventricular filling pressure, which is seen in decompensated heart failure. Patients with heart failure often have elevated jugular venous pressure and lower extremity edema, pulmonary examination findings are usually bilateral, and fevers and leukocytosis would not be expected.

(Choice B) Cold agglutinins (ie, IgM against erythrocyte I antigen) are nonspecific but often seen in patients with *Mycoplasma pneumoniae*. However, patients with *M pneumoniae* typically present with a dry cough and pharyngitis, and laboratory results demonstrate a mild hemolytic anemia with a normal leukocyte count. When pneumonia occurs due to *M pneumoniae*, examination findings are characteristically scattered and bilateral.

(Choices C and E) Prealbumin (transthyretin) and transferrin are negative APRs and would be decreased in this acutely ill patient. Prealbumin levels are also decreased in cases of malnutrition and may be helpful in evaluation of nutritional status. Transferrin is also used to determine iron status.

Educational objective:
Acute phase reactants (APRs) are proteins whose serum concentrations change by ≥25% during periods of inflammation. Procalcitonin is a unique APR that can rise or fall depending on the etiology of the infection; elevated levels correlate with a bacterial source, whereas low levels indicate a viral source.

References

- Role of procalcitonin in guiding antibiotic therapy.

Pathology	Infectious Diseases	Community acquired pneumonia
Subject	System	Topic

Copyright © UWorld. All rights reserved.

Settings

1
2
3
4
5
6
7
8
9

Item 4 of 9
Question Id: 60

Mark | Previous | Next | Full Screen | Tutorial | Lab Values | Notes | Calculator | Reverse Color | Text Zoom | Settings

The rates of hepatocellular carcinoma in some developing countries are many times higher than that in Western nations. A successful hepatocellular carcinoma prevention strategy in these countries would focus on incorporating:

A. Water sanitation
B. Vitamin supplementation
C. Universal vaccination
D. Adequate antibiotic use
E. Routine physician check-ups
F. Wider access to hospital care

Submit

Block Time Remaining: 00:00:08
TUTOR

1 | Feedback | Suspend | End Block

The rates of hepatocellular carcinoma in some developing countries are many times higher than that in Western nations. A successful hepatocellular carcinoma prevention strategy in these countries would focus on incorporating:

- A. Water sanitation (9%)
- B. Vitamin supplementation (0%)
- ✓ C. Universal vaccination (81%)
- D. Adequate antibiotic use (1%)
- E. Routine physician check-ups (4%)
- F. Wider access to hospital care (2%)

Omitted
Correct answer
C

81%
Answered correctly

01 sec
Time Spent

02/03/2020
Last Updated

Explanation

Worldwide, those countries with high rates of hepatitis B virus (HBV) infection have more than 85% of all hepatocellular carcinoma (HCC) cases. Korea, Taiwan, Mozambique, and China experience the highest annual rates of HCC (36 per 100,000 versus <5 per 100,000 in North America). The individuals who develop HCC in these countries usually have chronic HBV infection acquired through vertical transmission at childbirth, which increases their risk of developing HCC by early to middle adulthood 200-fold. In the United States, HCC normally arises after the age of 60. In these countries with high rates of HBV infection, however, HCC commonly presents in adults 20 to 40 years old.

Explanation

Worldwide, those countries with high rates of hepatitis B virus (HBV) infection have more than 85% of all hepatocellular carcinoma (HCC) cases. Korea, Taiwan, Mozambique, and China experience the highest annual rates of HCC (36 per 100,000 versus <5 per 100,000 in North America). The individuals who develop HCC in these countries usually have chronic HBV infection acquired through vertical transmission at childbirth, which increases their risk of developing HCC by early to middle adulthood 200-fold. In the United States, HCC normally arises after the age of 60. In these countries with high rates of HBV infection, however, HCC commonly presents in adults 20 to 40 years old.

Therefore, universal vaccination of children against HBV would be the one measure most likely to cause a steep decline in the incidence of hepatocellular carcinoma worldwide.

(Choice A) Improved water sanitation would be of significant help in reducing the incidence of many foodborne illnesses transmitted through the fecal-oral route (such as hepatitis A).

(Choice B) Vitamin supplementation would be of significant help in reducing the incidence of conditions associated with poor nutrition (eg, pellagra).

(Choice D) Adequate antibiotic usage would be of significant help in reducing the length and severity of bacterial infections.

(Choices E and F) Routine physician check-ups and wider access to hospital care would be of significant help in educating the patient population, identifying disease processes in early stages, and reducing suffering.

Educational Objective:
Universal vaccination of children against HBV would likely cause a steep decline in the worldwide incidence of hepatocellular carcinoma.

Pathology	Infectious Diseases	Hepatocellular cancer
Subject	System	Topic

Copyright © UWorld. All rights reserved.

Settings

1
2
3
4
5
6
7
8
9

Item 5 of 9
Question Id: 8290

Mark | Previous | Next | Full Screen | Tutorial | Lab Values | Notes | Calculator | Reverse Color | Text Zoom | Settings

A 46-year-old man comes to the physician complaining of intermittent, bloody diarrhea and abdominal pain for the past month. He has lost 12 lbs (5.5 kg) during this period. He was diagnosed with HIV five years ago, but has been noncompliant with his antiretroviral medications. Laboratory results show a CD4 count of 50 cells/μL and viral load of 650,000 copies/mL. Colonoscopy reveals multiple hemorrhagic polypoidal lesions. Biopsy of these lesions reveals spindle cells with surrounding blood vessel proliferation. Which of the following is the most likely cause of this patient's diarrhea?

A. Adenocarcinoma
B. Cytomegalovirus
C. Cryptosporidium
D. Entamoeba histolytica
E. Kaposi's sarcoma
F. Ulcerative colitis

Submit

Block Time Remaining: 00:00:09
TUTOR

7 | Feedback | Suspend | End Block

A 46-year-old man comes to the physician complaining of intermittent, bloody diarrhea and abdominal pain for the past month. He has lost 12 lbs (5.5 kg) during this period. He was diagnosed with HIV five years ago, but has been noncompliant with his antiretroviral medications. Laboratory results show a CD4 count of 50 cells/μL and viral load of 650,000 copies/mL. Colonoscopy reveals multiple hemorrhagic polypoidal lesions. Biopsy of these lesions reveals spindle cells with surrounding blood vessel proliferation. Which of the following is the most likely cause of this patient's diarrhea?

- A. Adenocarcinoma (9%)
- B. Cytomegalovirus (11%)
- C. Cryptosporidium (21%)
- D. Entamoeba histolytica (5%)
- ✓ E. Kaposi's sarcoma (48%)
- F. Ulcerative colitis (3%)

Omitted
Correct answer
E

48%
Answered correctly

01 sec
Time Spent

05/22/2020
Last Updated

Explanation

Colonic manifestations of various diseases		
Disease	Colonoscopy findings	Biopsy findings

Colonic manifestations of various diseases		
Disease	**Colonoscopy findings**	**Biopsy findings**
Adenocarcinoma	Usually a protuberant mass	Dysplastic mucosal cells with variable degree of gland formation
Cytomegalovirus	Multiple ulcers and mucosal erosions	Cytomegalic cells with inclusion bodies
Cryptosporidium	Nonulcerative inflammation	Basophilic clusters seen on the surface of intestinal mucosal cells
Entamoeba histolytica	Numerous discrete, flask-shaped ulcerative lesions	Trophozoites containing red blood cells
Kaposi's sarcoma	Reddish/violet, flat maculopapular lesions or hemorrhagic nodules	Spindle-shaped tumor cells with small-vessel proliferation
Ulcerative colitis	Contiguous area of erythematous, friable, granular mucosa with possible pseudopolyps	Inflammatory infiltrate involving the mucosa and submucosa with crypt abscesses

Causes of diarrhea in HIV patients include opportunistic and non-opportunistic infections as well as noninfectious causes such as Kaposi's sarcoma (KS). KS is a vascular malignancy caused by human herpesvirus 8 (HHV-8). HIV co-infection substantially increases the risk for developing KS. Skin involvement is characteristic, but extracutaneous spread of KS to the lungs and gastrointestinal tract is also common.

KS lesions are easily distinguished endoscopically. They vary from reddish/violet flat maculopapular lesions to raised hemorrhagic nodules or polypoid masses. On biopsy, KS lesions will typically show spindle cells with cytologic atypia, blood vessel proliferation, and extravasated red blood cells with hemosiderin deposition.

sarcoma (KS). KS is a vascular malignancy caused by human herpesvirus 8 (HHV-8). HIV co-infection substantially increases the risk for developing KS. Skin involvement is characteristic, but extracutaneous spread of KS to the lungs and gastrointestinal tract is also common.

KS lesions are easily distinguished endoscopically. They vary from reddish/violet flat maculopapular lesions to raised hemorrhagic nodules or polypoid masses. On biopsy, KS lesions will typically show spindle cells with cytologic atypia, blood vessel proliferation, and extravasated red blood cells with hemosiderin deposition.

(Choice A) Adenocarcinoma typically would show dysplastic mucosal cells with a variable degree of gland formation, depending on the differentiation of the tumor.

(Choice B) Colonoscopy in cytomegalovirus colitis would show multiple ulcers and mucosal erosions. Biopsy shows characteristic cytomegalic cells with inclusion bodies.

(Choice C) Cryptosporidiosis can cause profuse, watery, nonbloody diarrhea, particularly in patients with advanced AIDS (CD4 counts < 180 cells/mm^3). Endoscopy shows inflammation but no ulcers. Biopsy shows basophilic clusters on the surface of intestinal mucosal cells.

(Choice D) Entamoeba histolytica can cause bloody diarrhea and liver abscess formation. Colonoscopy would show the presence of flask-shaped colonic ulcers.

(Choice F) Colonoscopy in ulcerative colitis would show erythematous, friable, granular mucosa and possibly pseudopolyps (isolated areas of regenerative mucosa). An inflammatory infiltrate involving the mucosa and submucosa with crypt abscesses would be seen histologically.

Educational objective:
Kaposi's sarcoma usually involves the skin and GI tract and is common in HIV patients not on antiretroviral therapy. Endoscopy reveals characteristic lesions, which range from reddish/violet flat maculopapular lesions to raised hemorrhagic nodules or polypoid masses. Biopsy can show spindle cells, neovascularization, and extravasated red blood cells.

References

- Gastrointestinal malignancies in HIV-infected or immunosuppressed patients: pathologic features and review of the literature.

Pathology Infectious Diseases Kaposi sarcoma

Settings

1
2
3
4
5
6
7
8
9

Item 5 of 9
Question Id: 8290

Mark | Previous | Next | Full Screen | Tutorial | Lab Values | Notes | Calculator | Reverse Color | Text Zoom | Settings

sarcoma (KS). KS is a vascular malignancy caused by human herpesvirus 8 (HHV-8). HIV co-infection substantially increases the risk for

Exhibit Display

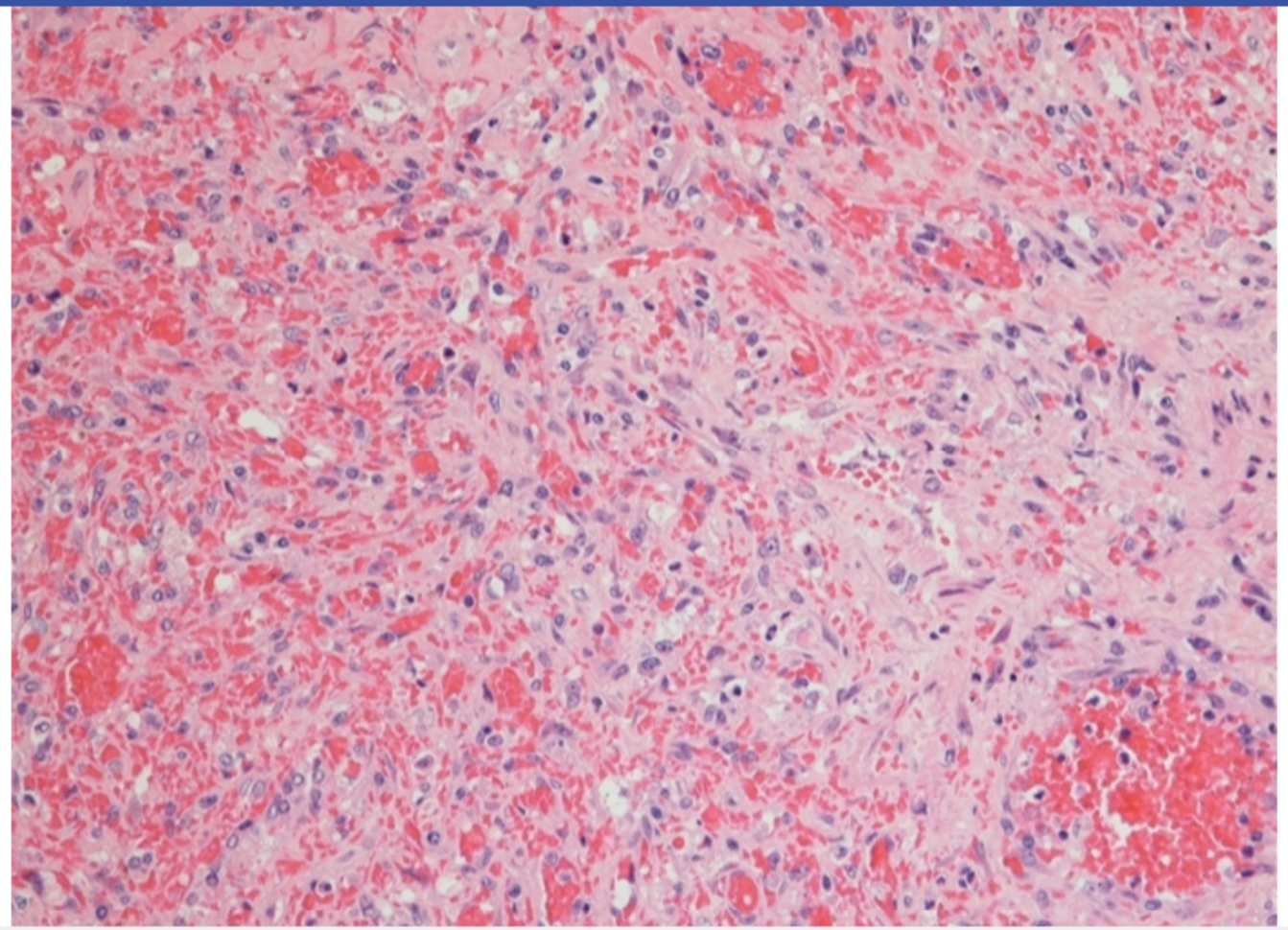

Zoom In | Zoom Out | Reset | Add To New Card | Existing Card

Block Time Remaining: 00:00:10
TUTOR

7 | Feedback | Suspend | End Block

Settings

1
2
3
4
5
6
7
8
9

Item 5 of 9
Question Id: 8290

Mark | Previous | Next | Full Screen | Tutorial | Lab Values | Notes | Calculator | Reverse Color | Text Zoom | Settings

sarcoma (KS). KS is a vascular malignancy caused by human herpesvirus 8 (HHV-8). HIV co-infection substantially increases the risk for

Exhibit Display

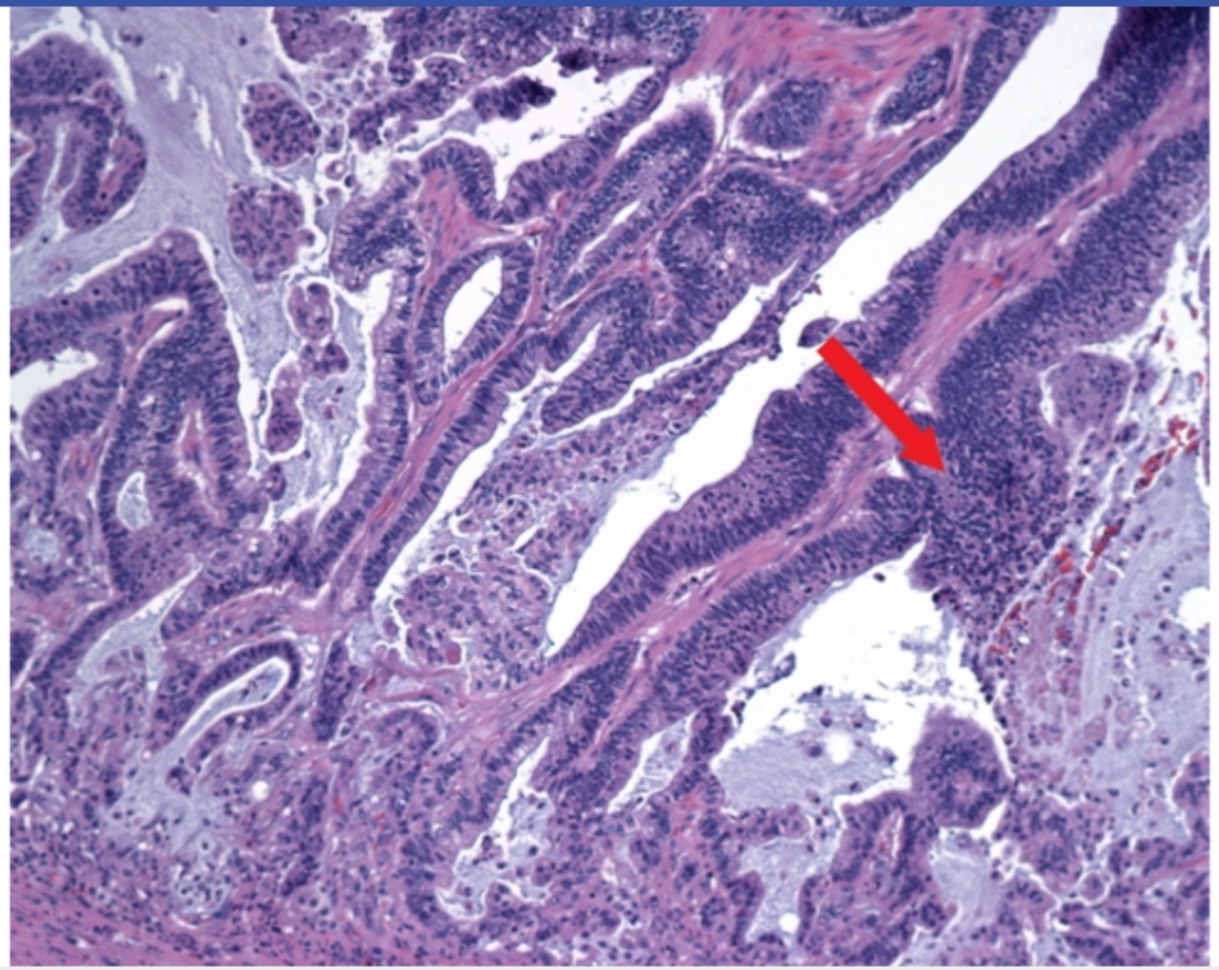

Zoom In | Zoom Out | Reset | Add To New Card | Existing Card

Block Time Remaining: 00:00:10
TUTOR

7 | Feedback | Suspend | End Block

Settings

1
2
3
4
5
6
7
8
9

Item 5 of 9
Question Id: 8290

Mark | Previous | Next | Full Screen | Tutorial | Lab Values | Notes | Calculator | Reverse Color | Text Zoom | Settings

sarcoma (KS). KS is a vascular malignancy caused by human herpesvirus 8 (HHV-8). HIV co-infection substantially increases the risk for

Exhibit Display

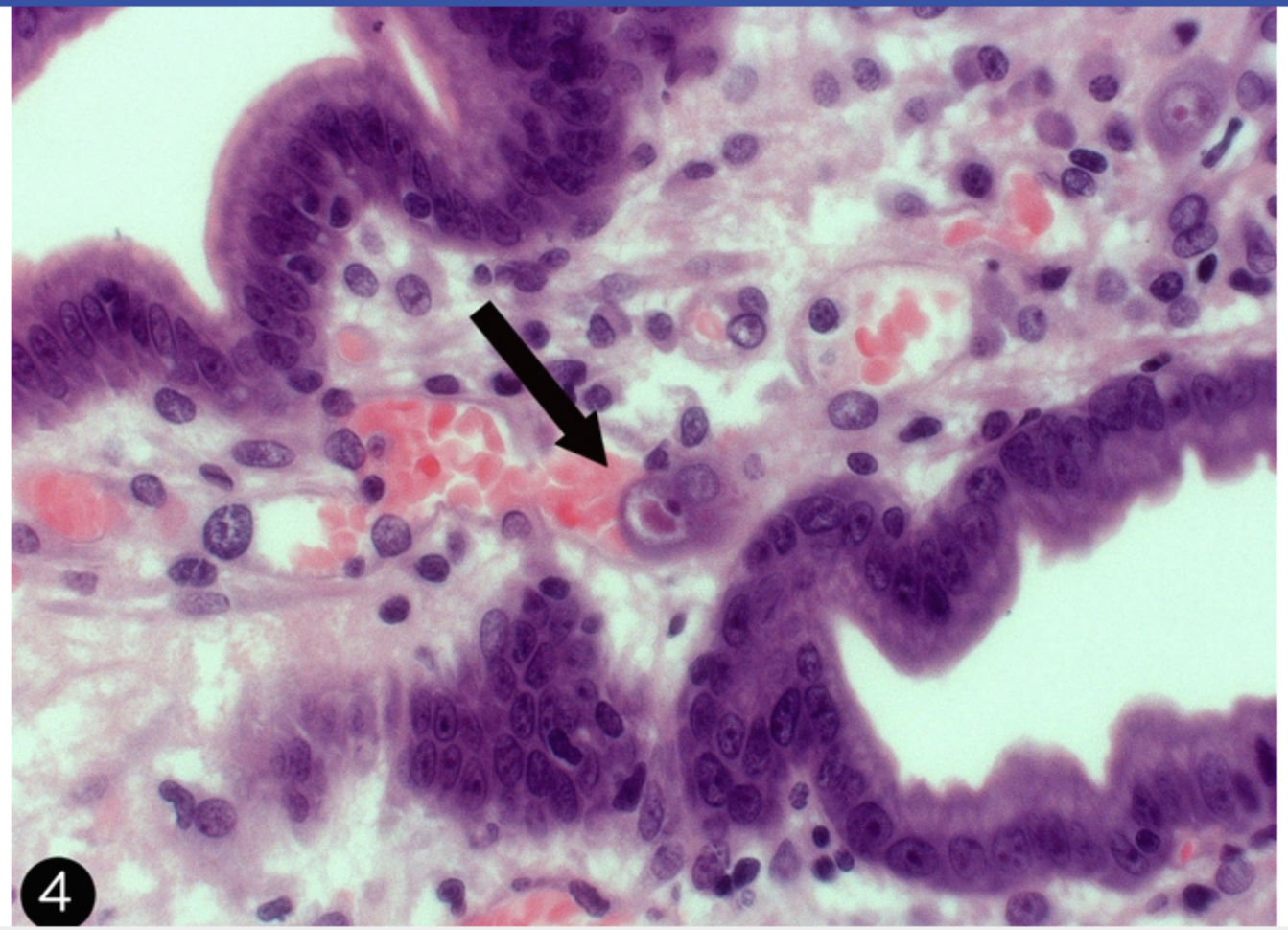

Zoom In | Zoom Out | Reset | Add To New Card | Existing Card

Block Time Remaining: 00:00:10
TUTOR

7 | Feedback | Suspend | End Block

Settings

1
2
3
4
5
6
7
8
9

Item 5 of 9
Question Id: 8290

Mark | Previous | Next | Full Screen | Tutorial | Lab Values | Notes | Calculator | Reverse Color | Text Zoom | Settings

sarcoma (KS). KS is a vascular malignancy caused by human herpesvirus 8 (HHV-8). HIV co-infection substantially increases the risk for

Exhibit Display

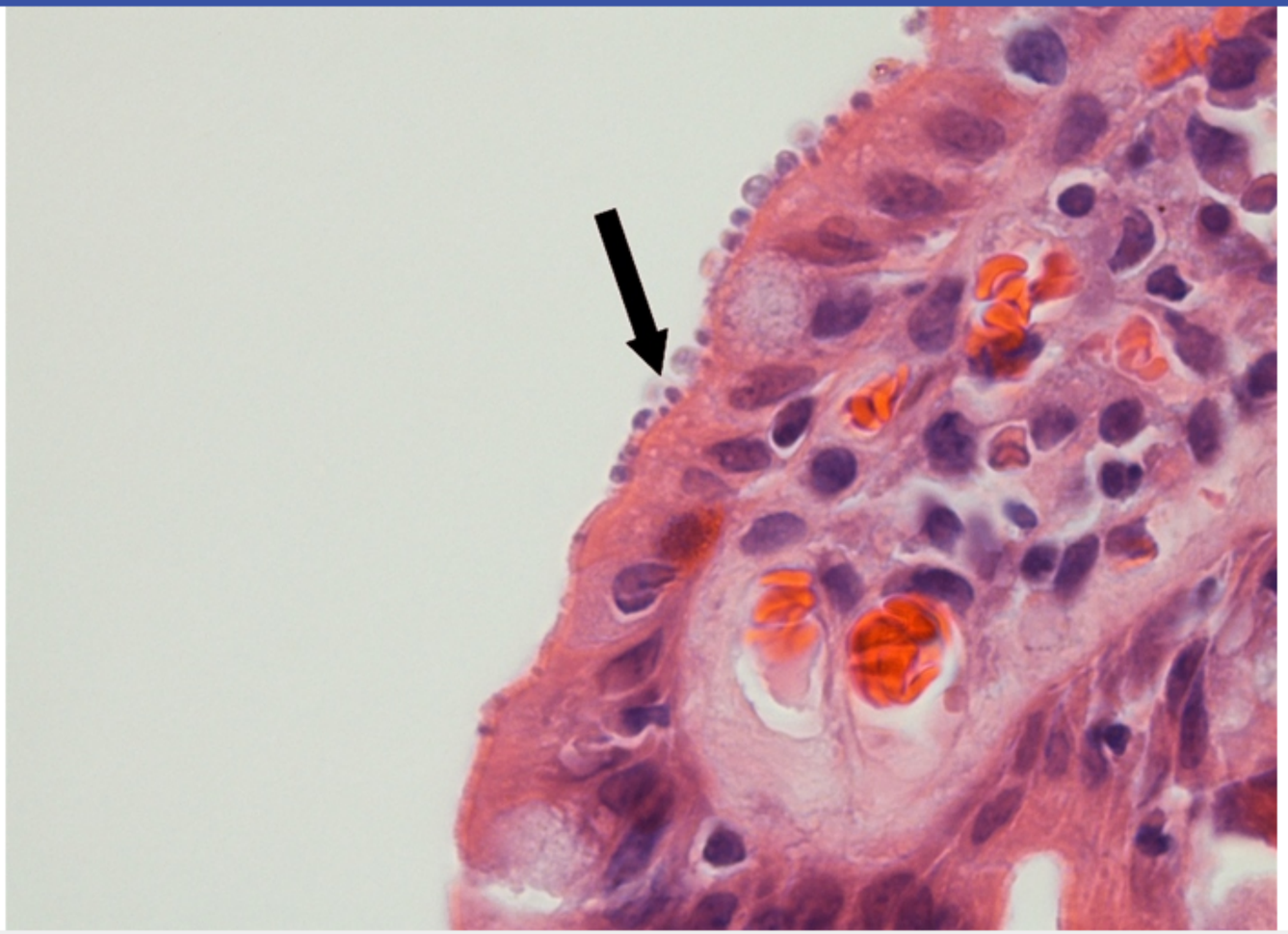

Zoom In | Zoom Out | Reset | Add To New Card | Existing Card

Block Time Remaining: 00:00:10
TUTOR

7 | Feedback | Suspend | End Block

Settings

1
2
3
4
5
6
7
8
9

Item 5 of 9
Question Id: 8290

Mark | Previous | Next | Full Screen | Tutorial | Lab Values | Notes | Calculator | Reverse Color | Text Zoom | Settings

sarcoma (KS). KS is a vascular malignancy caused by human herpesvirus 8 (HHV-8). HIV co-infection substantially increases the risk for

Exhibit Display

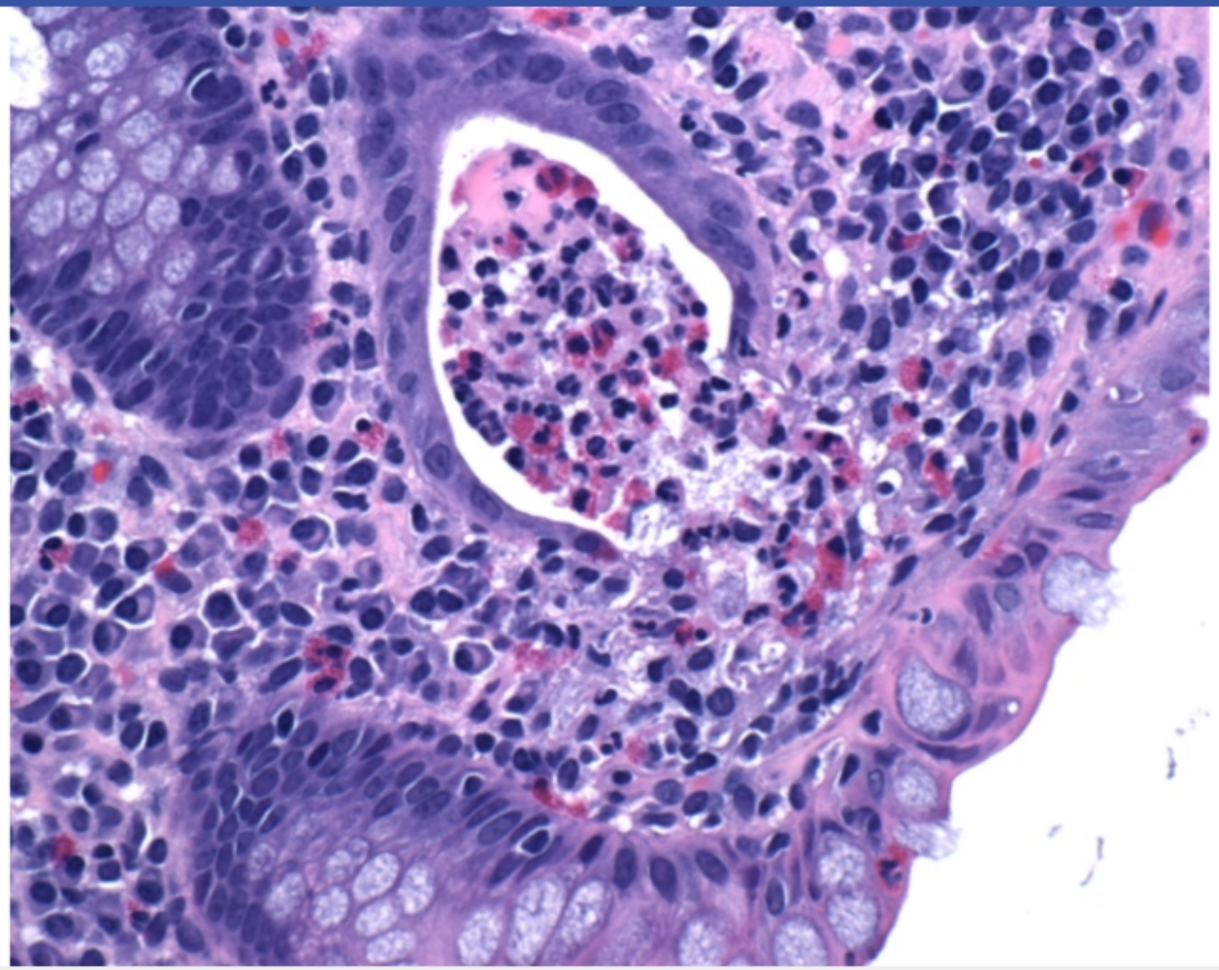

Zoom In | Zoom Out | Reset | Add To New Card | Existing Card

Block Time Remaining: 00:00:10
TUTOR

7 | Feedback | Suspend | End Block

Settings

1
2
3
4
5
6
7
8
9

Item 6 of 9
Question Id: 472

Mark | Previous | Next | Full Screen | Tutorial | Lab Values | Notes | Calculator | Reverse Color | Text Zoom | Settings

A 52-year-old man comes to the emergency department due to several days of vague chest pain and cough. He immigrated to the United States from Taiwan 20 years ago. Temperature is 37.1 C (98.8 F). Physical examination reveals a decrescendo-type diastolic murmur over the right sternal border. Pulmonary auscultation reveals normal breath sounds with no wheezes or rales. Abdominal examination shows no organomegaly. Serum fluorescent treponemal antibody absorption testing is positive. Chest x-ray reveals mediastinal widening. The pathologic process most likely responsible for this patient's symptoms starts as which of the following?

A. Intimal streak

B. Intimal tear

C. Medial degeneration

D. Medial inflammation

E. Vasa vasorum obliteration

Submit

Block Time Remaining: 00:00:10
TUTOR

1 | Feedback | Suspend | End Block

A 52-year-old man comes to the emergency department due to several days of vague chest pain and cough. He immigrated to the United States from Taiwan 20 years ago. Temperature is 37.1 C (98.8 F). Physical examination reveals a decrescendo-type diastolic murmur over the right sternal border. Pulmonary auscultation reveals normal breath sounds with no wheezes or rales. Abdominal examination shows no organomegaly. Serum fluorescent treponemal antibody absorption testing is positive. Chest x-ray reveals mediastinal widening. The pathologic process most likely responsible for this patient's symptoms starts as which of the following?

- A. Intimal streak (2%)
- B. Intimal tear (7%)
- C. Medial degeneration (6%)
- D. Medial inflammation (10%)
- ✓ E. Vasa vasorum obliteration (72%)

Omitted
Correct answer
E

72%
Answered correctly

02 secs
Time Spent

06/03/2020
Last Updated

Explanation

This patient's murmur is characteristic of **aortic regurgitation**, which, in the presence of mediastinal widening, suggests an **aortic aneurysm** that has dilated the aortic annulus. The positive serology for **syphilis** (positive fluorescent treponemal antibody absorption [FTA-ABS] test) suggests a "luetic" aneurysm, consistent with tertiary syphilis.

Tertiary syphilis begins with **vasa vasorum endarteritis** and obliteration, resulting in inflammation, ischemia, and weakening of the adventitia.

This patient's murmur is characteristic of **aortic regurgitation**, which, in the presence of mediastinal widening, suggests an **aortic aneurysm** that has dilated the aortic annulus. The positive serology for **syphilis** (positive fluorescent treponemal antibody absorption [FTA-ABS] test) suggests a "luetic" aneurysm, consistent with tertiary syphilis.

Tertiary syphilis begins with **vasa vasorum endarteritis** and obliteration, resulting in inflammation, ischemia, and weakening of the adventitia. Aneurysmal dilation of the thoracic aorta results and can extend to involve the aortic valve ring. Syphilitic aneurysms are uncommon in the United States.

(Choice A) Intimal streaks are the earliest lesions of atherosclerosis. Severe, complicated intimal atheromas can destroy and weaken the underlying media, resulting in aortic aneurysms. However, the most common site of these lesions is in the abdominal aorta (below the origin of the renal arteries). Although atherosclerosis can promote aneurysm formation in the thoracic aorta, the positive FTA-ABS test makes atherosclerosis less likely to be the cause of this patient's symptoms.

(Choices B and C) Intimal tear and medial degeneration (elastic tissue fragmentation and separation of the elastic and fibromuscular components of the tunica media by small, cleft-like spaces) are common histopathologic abnormalities seen with aortic dissections (severe chest pain radiating to the back), not aortic aneurysms.

(Choice D) Large vessel arteritides with medial inflammation (eg, Takayasu, giant cell arteritis) might rarely promote an aortic aneurysm; however, they are not associated with a positive serology for syphilis.

Educational objective:
Tertiary syphilis can result in thoracic aortic aneurysm. If the aneurysm compresses adjacent structures and dilates the aortic valve ring, a murmur and mediastinal widening might be present. The pathogenesis begins with vasa vasorum endarteritis and obliteration, resulting in inflammation, ischemia, and weakening of the aortic adventitia. Fluorescent treponemal antibody absorption testing is specific for syphilis.

Pathology	Infectious Diseases	Syphilis
Subject	System	Topic

Copyright © UWorld. All rights reserved.

A 27-year-old man comes to the office due to a 2-week history of genital papules that are not painful or pruritic. Over this period, he has also had fatigue and mild, generalized arthralgia but no urethral discharge or dysuria. The patient had gonococcal urethritis 3 months ago, which was adequately treated, and tests for other sexually transmitted infections at that time were negative. He is sexually active with several male and female partners and reports using condoms consistently after the episode of gonorrhea. Temperature is 37.6 C (99.6 F). Physical examination shows a faint, diffuse maculopapular skin rash involving the trunk, extremities, palms, and soles. There are several enlarged, nontender inguinal lymph nodes. Genital examination reveals multiple, raised, wart-like skin lesions on the scrotum and perineal region. Histopathologic evaluation of these lesions would most likely reveal which of the following in this patient?

A. Acantholysis with superficial dermal lymphocytic infiltrate

B. Dysplastic spindle cells with viral genome that form vascular channels

C. Intense plasma cell–rich infiltrate with proliferative endarteritis

D. Panniculitis and septal inflammation with multinucleated giant cells

E. Papillomatous epidermal hyperplasia with cytoplasmic vacuolization

Submit

A 27-year-old man comes to the office due to a 2-week history of genital papules that are not painful or pruritic. Over this period, he has also had fatigue and mild, generalized arthralgia but no urethral discharge or dysuria. The patient had gonococcal urethritis 3 months ago, which was adequately treated, and tests for other sexually transmitted infections at that time were negative. He is sexually active with several male and female partners and reports using condoms consistently after the episode of gonorrhea. Temperature is 37.6 C (99.6 F). Physical examination shows a faint, diffuse maculopapular skin rash involving the trunk, extremities, palms, and soles. There are several enlarged, nontender inguinal lymph nodes. Genital examination reveals multiple, raised, wart-like skin lesions on the scrotum and perineal region. Histopathologic evaluation of these lesions would most likely reveal which of the following in this patient?

- A. Acantholysis with superficial dermal lymphocytic infiltrate (6%)
- B. Dysplastic spindle cells with viral genome that form vascular channels (4%)
- ✓ C. Intense plasma cell–rich infiltrate with proliferative endarteritis (38%)
- D. Panniculitis and septal inflammation with multinucleated giant cells (7%)
- E. Papillomatous epidermal hyperplasia with cytoplasmic vacuolization (42%)

Omitted
Correct answer
C

38%
Answered correctly

02 secs
Time Spent

05/25/2020
Last Updated

Explanation

Syphilis manifestations	

Explanation

Syphilis manifestations	
Primary	• Painless genital ulcer (chancre)
Secondary	• Diffuse rash (palms & soles) • Lymphadenopathy (epitrochlear) • Condyloma latum • Oral lesions • Hepatitis
Latent	• Asymptomatic
Tertiary	• CNS (tabes dorsalis, dementia) • Cardiovascular (aortic aneurysm/insufficiency) • Cutaneous (gummas)

CNS = central nervous system.

Secondary syphilis is characterized by the spread of the causative spirochete, *Treponema pallidum*, through the blood to the skin and mucosal surfaces. Patients usually have a diffuse maculopapular skin rash that includes the palms and soles. They may also develop **condylomata lata**, which are painless, wart-like, elevated plaques, on moist areas of the skin such as the scrotum and perineum. Lymphadenopathy, fatigue, arthralgias, and mild fever are also common. Histopathologic examination of syphilitic lesions (at all stages) classically demonstrates **proliferative endarteritis** of small vessels with a surrounding plasma cell–rich infiltrate.

This patient was likely infected with syphilis at the same time he was infected with gonorrhea (coinfection is common). Serologic testing for syphilis (eg, rapid plasma reagin) is often falsely negative in early infection due to lag time between acquisition of *T pallidum* and the development of a measurable humoral antibody response. Patients who do not notice or ignore the genital chancre of primary syphilis often develop secondary syphilis 2 – 10 weeks later.

CNS = central nervous system.

Secondary syphilis is characterized by the spread of the causative spirochete, *Treponema pallidum*, through the blood to the skin and mucosal surfaces. Patients usually have a diffuse maculopapular skin rash that includes the palms and soles. They may also develop **condylomata lata**, which are painless, wart-like, elevated plaques, on moist areas of the skin such as the scrotum and perineum. Lymphadenopathy, fatigue, arthralgias, and mild fever are also common. Histopathologic examination of syphilitic lesions (at all stages) classically demonstrates **proliferative endarteritis** of small vessels with a surrounding plasma cell–rich infiltrate.

This patient was likely infected with syphilis at the same time he was infected with gonorrhea (coinfection is common). Serologic testing for syphilis (eg, rapid plasma reagin) is often falsely negative in early infection due to lag time between acquisition of *T pallidum* and the development of a measurable humoral antibody response. Patients who do not notice or ignore the genital chancre of primary syphilis often develop secondary syphilis 2 – 10 weeks later.

(Choice A) Pemphigus vulgaris is characterized by autoantibodies against epithelial cell surface antigens, leading to the formation of mucous membrane blisters that quickly erode; histopathology usually shows acantholysis (detached keratinocytes) with superficial dermal infiltrate.

(Choice B) Kaposi sarcoma (KS) lesions appear as whirls of dysplastic spindle-shaped cells surrounding areas of angioproliferation. KS is due to human herpesvirus 8 infection and most commonly occurs in the setting of advanced AIDS. Lesions typically appear as purplish or dark brown plaques and nodules on the lower extremities.

(Choice D) Biopsy of erythema nodosum lesions usually reveals septal panniculitis with multinucleated giant cells. Erythema nodosum is a delayed-type hypersensitivity reaction that can occur due to drugs or other antigenic stimuli. Patients usually present with tender nodules on the bilateral shins.

(Choice E) Biopsy of anogenital warts will demonstrate papillomatous epidermal hyperplasia with cytoplasmic vacuolization. Anogenital warts are caused by specific serotypes of human papillomavirus (eg, HPV-6, HPV-11). Anogenital warts are not typically associated with diffuse maculopapular rash or systemic symptoms.

Educational objective:
Histopathologic examination of syphilitic lesions classically demonstrates a proliferative endarteritis with a surrounding plasma cell infiltrate. Most

CNS = central nervous system

Exhibit Display

Secondary syphilis

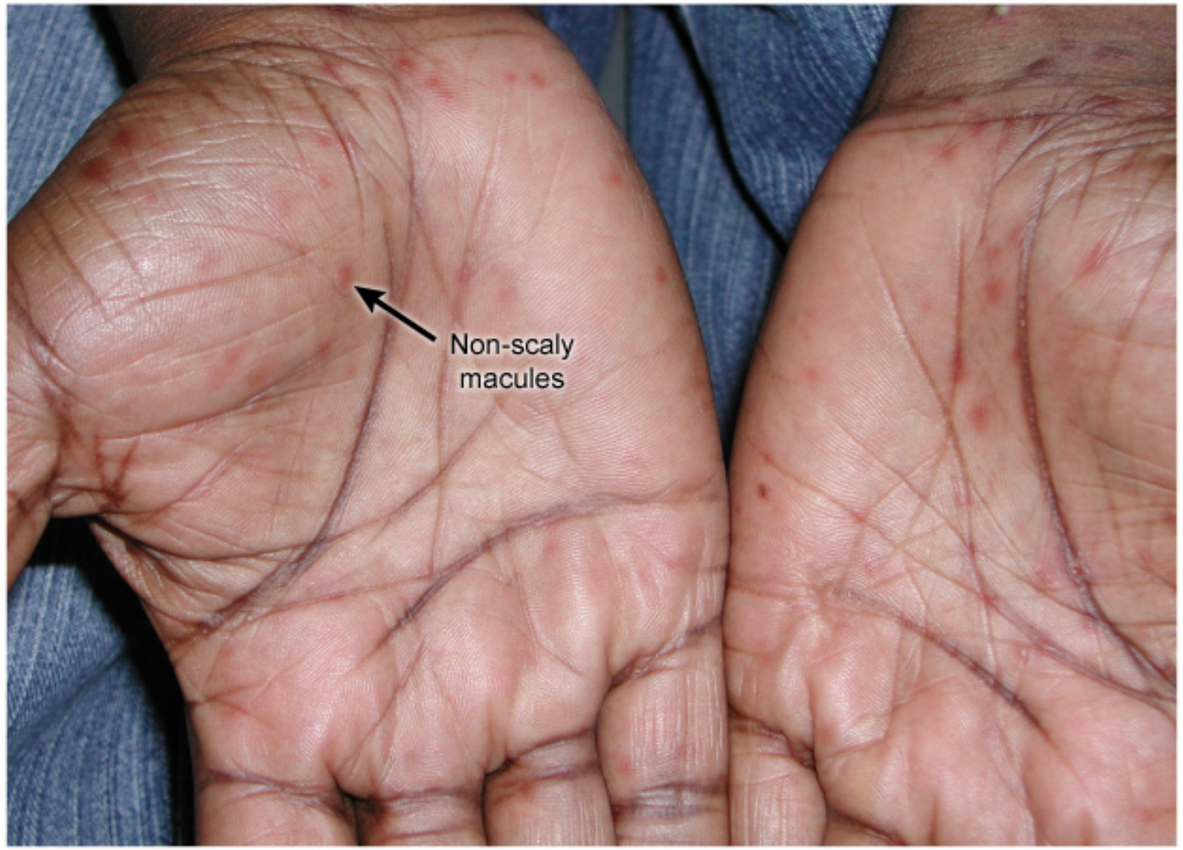

©UWorld

Zoom In | Zoom Out | Reset | Add To New Card | Existing Card

Settings

1
2
3
4
5
6
7
8
9

Item 7 of 9
Question Id: 14855

Mark | Previous | Next | Full Screen | Tutorial | Lab Values | Notes | Calculator | Reverse Color | Text Zoom | Settings

CNS = central nervous system

Exhibit Display

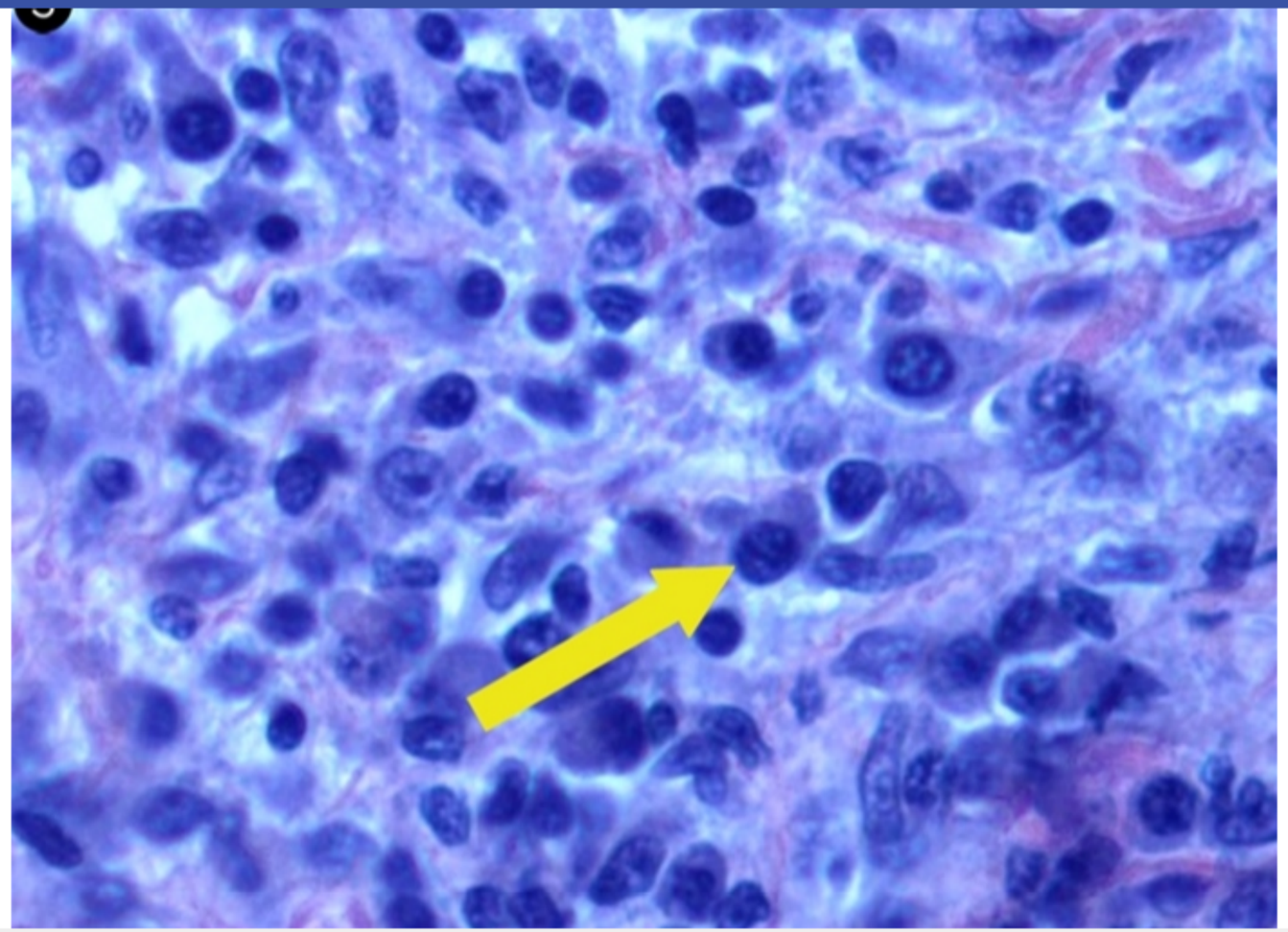

Zoom In | Zoom Out | Reset | Add To New Card | Existing Card

Block Time Remaining: 00:00:14
TUTOR

6 | Feedback | Suspend | End Block

Settings

1
2
3
4
5
6
7
8
9

Item 7 of 9
Question Id: 14855

Mark | Previous | Next | Full Screen | Tutorial | Lab Values | Notes | Calculator | Reverse Color | Text Zoom | Settings

CNS = central nervous system

Exhibit Display

Zoom In | Zoom Out | Reset | Add To New Card | Existing Card

Block Time Remaining: 00:00:14
TUTOR

6 | Feedback | Suspend | End Block

A 26-year-old man comes to the office due to 2 days of rash on his right thigh. It is mildly pruritic and not painful. He has no chronic medical conditions but occasionally takes ibuprofen for shoulder pain following intensive workouts at the gym. Temperature is 37.2 C (98.6 F), blood pressure is 115/78 mm Hg, and pulse is 94/min. The rash is shown in the image below:

No other lesions are seen. Which of the following is the most likely underlying cause of this patient's rash?

A. Drug-induced cytotoxic T-cell activation

B. Fungal infection due to shared gym equipment

C. Type 1 hypersensitivity reaction to an insect bite

D. Spread of spirochetes through the dermis

E. Spread of *Streptococcus* through lymphatic channels

Submit

No other lesions are seen. Which of the following is the most likely underlying cause of this patient's rash?

A. Drug-induced cytotoxic T-cell activation (6%)

B. Fungal infection due to shared gym equipment (7%)

C. Type 1 hypersensitivity reaction to an insect bite (17%)

✓ D. Spread of spirochetes through the dermis (68%)

E. Spread of *Streptococcus* through lymphatic channels (0%)

Omitted
Correct answer

68%
Answered correctly

04 secs
Time Spent

02/20/2020
Last Updated

Explanation

This patient's annular, erythematous rash with central clearing suggests **erythema migrans** (EM), the hallmark feature of early localized **Lyme disease**. Lyme disease is caused by the spirochete *Borrelia burgdorferi* and is transmitted by the *Ixodes scapularis* tick during blood feeding. *B burgdorferi* replicates at the site of inoculation, which generates a rash 7-14 days after transmission in most patients.

EM typically begins as a confluent macule that expands outward as *B burgdorferi* **spreads through the dermis**. Most cases evolve over days into an **annular lesion with central clearing**, which resembles a **bull's-eye**. Pain is rare, and pruritis is typically mild or absent. However, some patients have systemic manifestations (eg, malaise, fever, headache). Because many patients with Lyme disease do not recall a tick bite, suspicion for Lyme disease should be raised in any individual from an endemic area who develops a characteristic EM rash.

(Choice A) Nonsteroidal anti-inflammatory drugs (eg, ibuprofen) can sometimes cause a fixed drug reaction, which is marked by the activation of cytotoxic T cells in a particular location within the dermis. Although patients frequently develop an annular rash, it is usually a dusky red plaque with no central clearing.

(Choice B) Tinea corporis can sometimes be spread through contact with fomites (eg, gym equipment). Although this fungal infection often causes an annular lesion with central clearing that spreads outward, the advancing edge has raised borders, and the lesions are usually intensely pruritic.

(Choice C) A type 1 hypersensitivity (allergic) reaction to an insect bite usually arises within minutes and is marked by an edematous lesion that is intensely pruritic. This patient with 2 days of progressive rash that is nonpruritic is unlikely to be experiencing an allergic reaction.

(Choice E) *Streptococcal* lymphangitis is marked by the formation of erythematous streaks up the lymphatic channel. The formation of an annular lesion with central clearing would be atypical.

Educational objective:
Lyme disease should be suspected in any individual from an endemic area who develops erythema migrans, a slowly expanding annular lesion with central clearing (bull's-eye rash). Most cases are not pruritic or painful, but patients sometimes have systemic symptoms (eg, fever, myalgia, headache).

References

Settings

1
2
3
4
5
6
7
8
9

Item 8 of 9
Question Id: 1676

Mark | Previous | Next | Full Screen | Tutorial | Lab Values | Notes | Calculator | Reverse Color | Text Zoom | Settings

Explanation

Exhibit Display

Lyme Disease: Endemic Areas in the United States

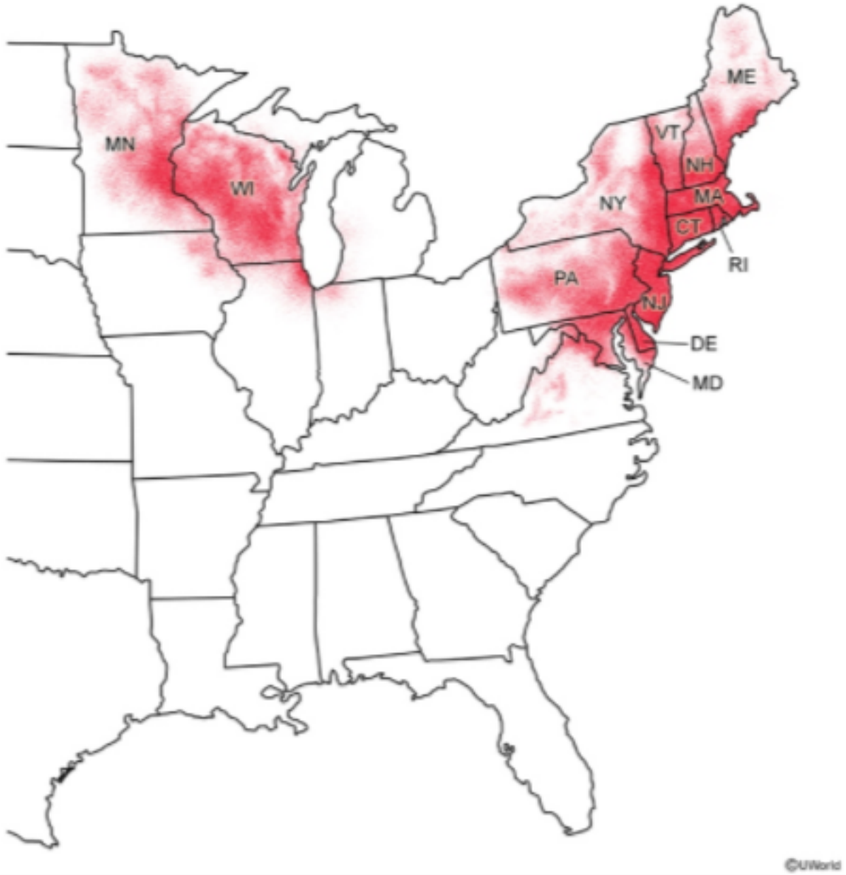

Zoom In | Zoom Out | Reset | Add To New Card | Existing Card

References

Block Time Remaining: 00:00:18
TUTOR

7 | Feedback | Suspend | End Block

Settings

1
2
3
4
5
6
7
8
9

Item 8 of 9
Question Id: 1676

Mark | Previous | Next | Full Screen | Tutorial | Lab Values | Notes | Calculator | Reverse Color | Text Zoom | Settings

Explanation

Exhibit Display

Zoom In | Zoom Out | Reset | Add To New Card | Existing Card

References

Block Time Remaining: 00:00:18
TUTOR

7 | Feedback | Suspend | End Block

Settings

1
2
3
4
5
6
7
8
9

Item 8 of 9
Question Id: 1676

Mark | Previous | Next | Full Screen | Tutorial | Lab Values | Notes | Calculator | Reverse Color | Text Zoom | Settings

Explanation

Exhibit Display

Zoom In | Zoom Out | Reset | Add To New Card | Existing Card

References

Block Time Remaining: 00:00:18
TUTOR

7 | Feedback | Suspend | End Block

A 3-year-old boy is brought to the emergency department due to high fever, vomiting, and lethargy. His symptoms started 1 day ago but rapidly worsened over the last few hours. Physical examination shows hypotension, tachycardia, neck stiffness, and a petechial rash over the trunk and lower extremities. Laboratory results are as follows:

Complete blood count	
Hemoglobin	12.0 g/L
Platelets	80,000/mm^3
Leukocytes	34,500/mm^3
Neutrophils	66%
Band forms	20%
Lymphocytes	14%
Chemistry panel	
Blood urea nitrogen	30 mg/dL
Serum creatinine	1.8 mg/dL
Blood glucose	50 mg/dL

While being evaluated, the patient develops apnea and asystole. Despite aggressive resuscitation efforts, the patient dies. Autopsy would most likely reveal which of the following?

A. Adrenal hemorrhage

B. Cardiac tamponade

Leukocytes	34,500/mm^3
Neutrophils	66%
Band forms	20%
Lymphocytes	14%

Chemistry panel

Blood urea nitrogen	30 mg/dL
Serum creatinine	1.8 mg/dL
Blood glucose	50 mg/dL

While being evaluated, the patient develops apnea and asystole. Despite aggressive resuscitation efforts, the patient dies. Autopsy would most likely reveal which of the following?

A. Adrenal hemorrhage
B. Cardiac tamponade
C. Intracerebral hemorrhage
D. Necrotizing pancreatitis
E. Saddle pulmonary embolus

Submit

Leukocytes	34,500/mm^3
Neutrophils	66%
Band forms	20%
Lymphocytes	14%

Chemistry panel

Blood urea nitrogen	30 mg/dL
Serum creatinine	1.8 mg/dL
Blood glucose	50 mg/dL

While being evaluated, the patient develops apnea and asystole. Despite aggressive resuscitation efforts, the patient dies. Autopsy would most likely reveal which of the following?

- ✓ A. Adrenal hemorrhage (80%)
- B. Cardiac tamponade (2%)
- C. Intracerebral hemorrhage (11%)
- D. Necrotizing pancreatitis (2%)
- E. Saddle pulmonary embolus (3%)

Omitted
Correct answer

80%
Answered correctly

04 secs
Time Spent

04/20/2020
Last Updated

Explanation

Meningococcal meningitis	
Epidemiology	• *Neisseria meningitidis* • Most common in children and young adults
Pathophysiology	• Nasopharyngeal colonization • Epithelial cell invasion • Immune system evasion (eg, capsule, variable pili)
Clinical features	• Fever, headache, vomiting, severe myalgias • Petechial/purpuric rash • Altered mental status, neck stiffness
Complications	• Septic shock, multiorgan failure • Adrenal hemorrhage/insufficiency • Disseminated intravascular coagulation

This patient's rapidly worsening fever, vomiting, altered mental status, and nuchal rigidity are consistent with **meningococcal meningitis** due to infection with *Neisseria meningitidis*. Meningococcal infection usually occurs in children and young adults and can present acutely with rapid progression (within hours) to **meningococcemia** and **septic shock**. These patients frequently have thrombocytopenia and a petechial rash and are at risk for development of disseminated intravascular coagulation.

A serious complication of meningococcemia is **bilateral hemorrhagic infarction** of the adrenal glands , resulting in acute adrenal insufficiency (Waterhouse-Friderichsen syndrome). Manifestations include **hypoglycemia** due to cortisol deficiency as well as **hyponatremia** and **hyperkalemia** due to aldosterone deficiency. Loss of cortisol and aldosterone also contributes to worsening shock and can result in **rapid deterioration** and death despite aggressive intervention.

(Choices B and E) Both cardiac tamponade and a saddle pulmonary embolus can cause obstructive shock that results in multiorgan failure.

This patient's rapidly worsening fever, vomiting, altered mental status, and nuchal rigidity are consistent with **meningococcal meningitis** due to infection with *Neisseria meningitidis*. Meningococcal infection usually occurs in children and young adults and can present acutely with rapid progression (within hours) to **meningococcemia** and **septic shock**. These patients frequently have thrombocytopenia and a petechial rash and are at risk for development of disseminated intravascular coagulation.

A serious complication of meningococcemia is **bilateral hemorrhagic infarction** of the adrenal glands , resulting in acute adrenal insufficiency (Waterhouse-Friderichsen syndrome). Manifestations include **hypoglycemia** due to cortisol deficiency as well as **hyponatremia** and **hyperkalemia** due to aldosterone deficiency. Loss of cortisol and aldosterone also contributes to worsening shock and can result in **rapid deterioration** and death despite aggressive intervention.

(Choices B and E) Both cardiac tamponade and a saddle pulmonary embolus can cause obstructive shock that results in multiorgan failure. However, shock due to these conditions is not usually associated with adrenal insufficiency, and this patient's other clinical features (eg, neck stiffness, rash) suggest meningococcal meningitis as the primary cause.

(Choice C) Intracerebral hemorrhage with increasing intracranial pressure can present with severe headache, vomiting, altered mental status, loss of consciousness, and death. Neck stiffness may be present if the hemorrhage extends into the subarachnoid space and irritates the meninges. However, this patient's fever, petechial rash, and adrenal insufficiency make meningococcal meningitis more likely.

(Choice D) Necrotizing pancreatitis typically presents with worsening abdominal pain and vomiting, and if infected can lead to septic shock and death. However, it is not associated with neck stiffness and a petechial rash.

Educational objective:
Meningococcal meningitis is a rapidly progressive infection that can spread systemically (ie, meningococcemia) and lead to septic shock, multiorgan failure, and disseminated intravascular coagulation. Meningococcemia is also associated with bilateral hemorrhagic infarction of the adrenal glands, which can result in acute adrenal insufficiency (Waterhouse-Friderichsen syndrome) with worsening shock and rapid clinical deterioration.

References

- Waterhouse-Friderichsen syndrome.
- The significance of adrenal hemorrhage: undiagnosed Waterhouse-Friderichsen syndrome, a case series.

This patient's rapidly worsening fever, vomiting, altered mental status, and nuchal rigidity are consistent with **meningococcal meningitis** due to

Exhibit Display

Waterhouse-Friderichsen syndrome

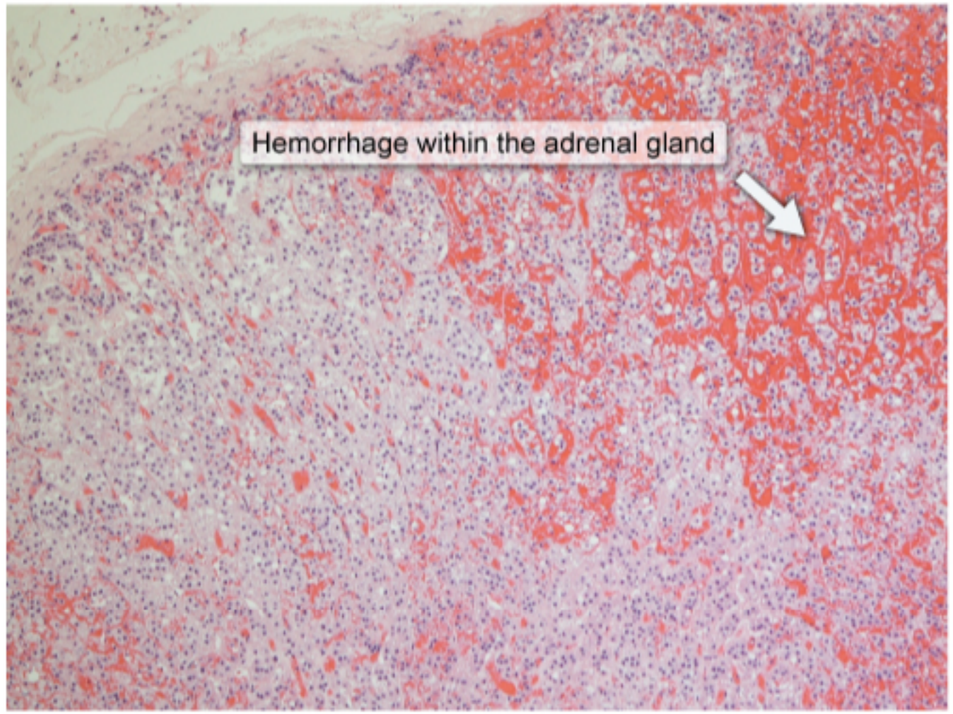

©UWorld

Zoom In | Zoom Out | Reset | Add To New Card | Existing Card